

# c<sup>o</sup>vid-project

Collaborative Learning of Viewing and Decision-making Skills

Seminar Amsterdam

Date: 19.05.2022

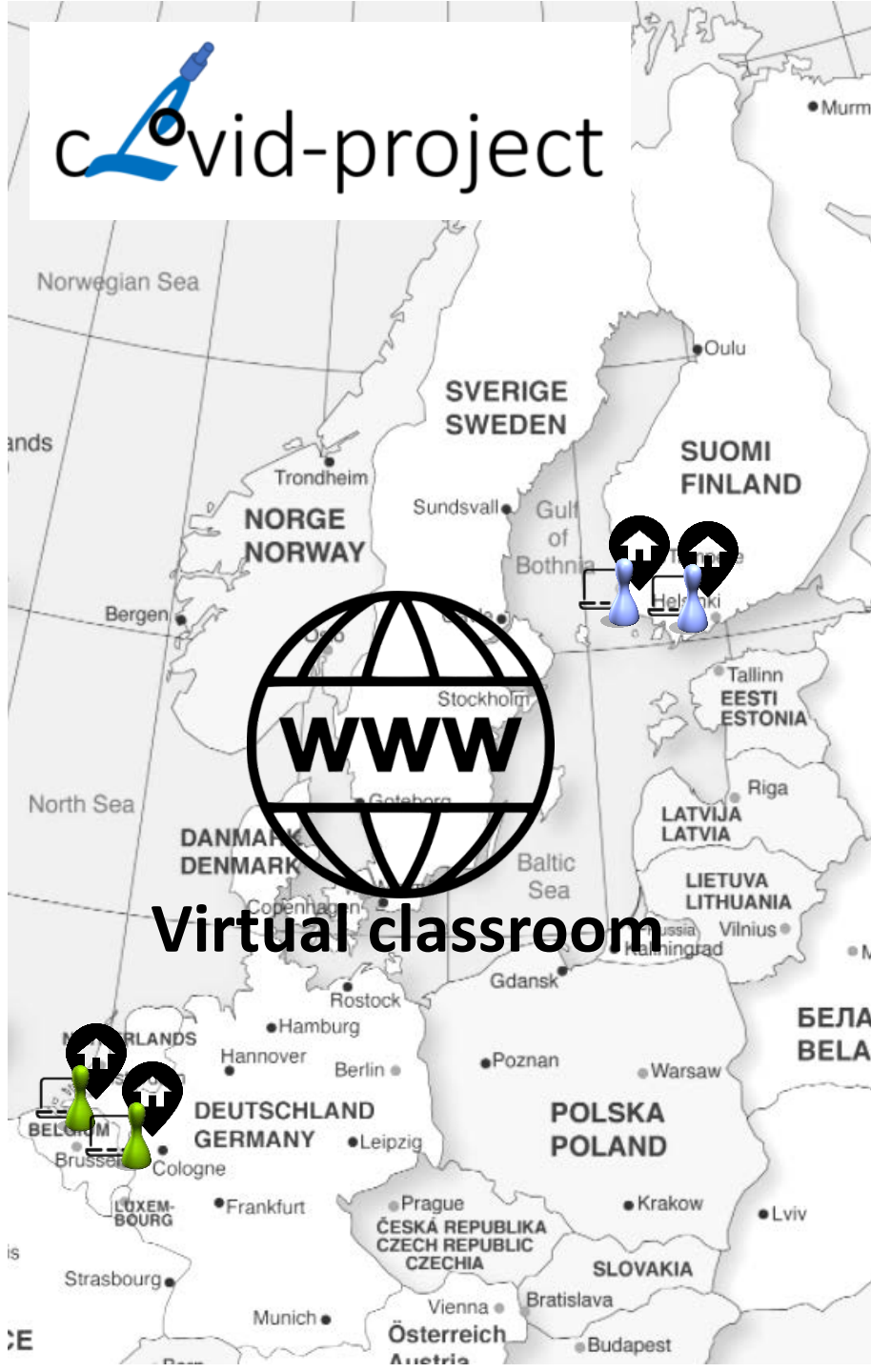
Dr. Bas de Leng: WWU Münster,  
Institute of Medical Education and Student Affairs (IfAS)

# General information

Website: <https://medicampus.uni-muenster.de/ccel/projects/clovid/>

- EU-project for 'digital education readiness'
- From March 2021 to March 2023
- Three strategic partners



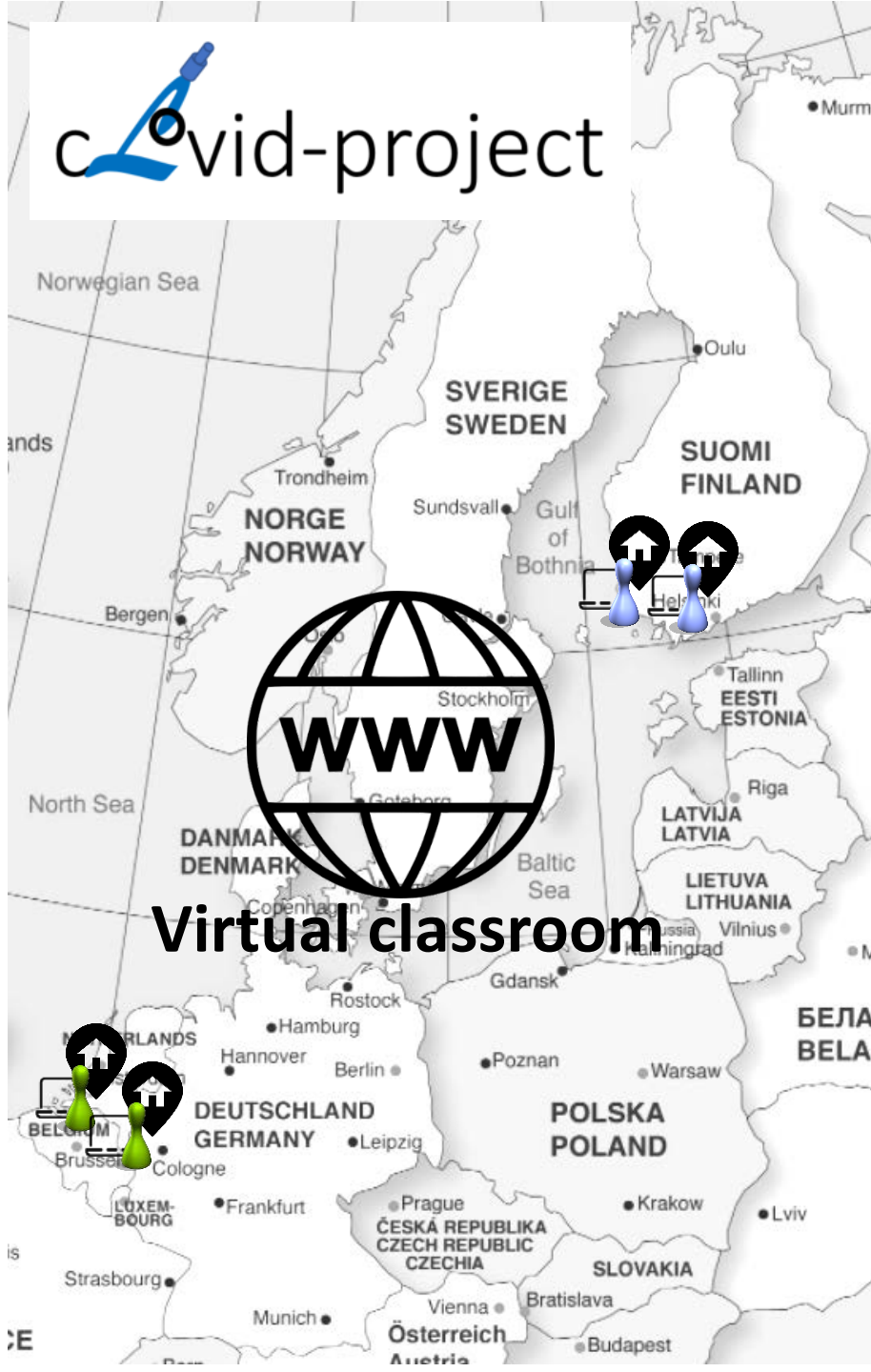


Virtual classroom

## Goals

- Overarching: to enable online collaborative learning scenarios for visually based subjects, using huge high-resolution 2D images (tiled whole slide images)
- Exemplary case: microscopic pathology education at undergraduate medical schools

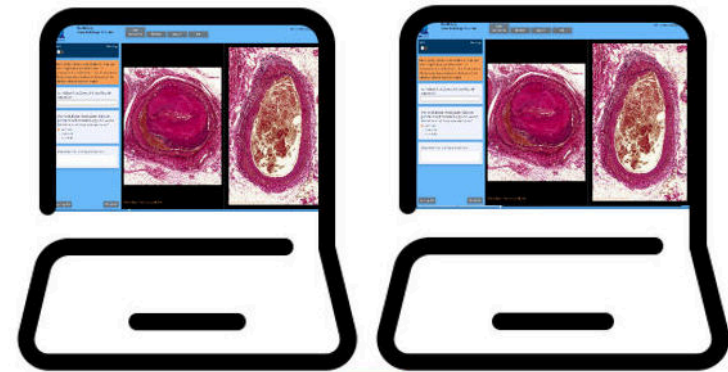



## Microscopic Pathology

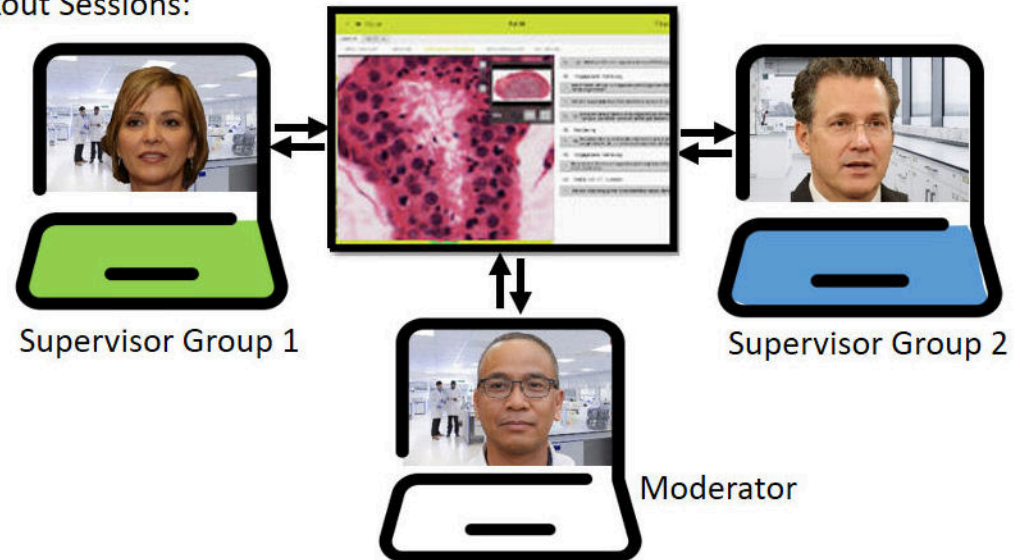
### 1 Individual: Online VQuest

- 1. Web-Browser at home
  - Individual assignment:

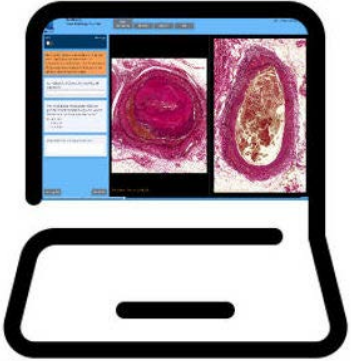

- 2. Video Conference with supervisors
  - Breakout Sessions:

### 2 Groups: Learning Dashboard

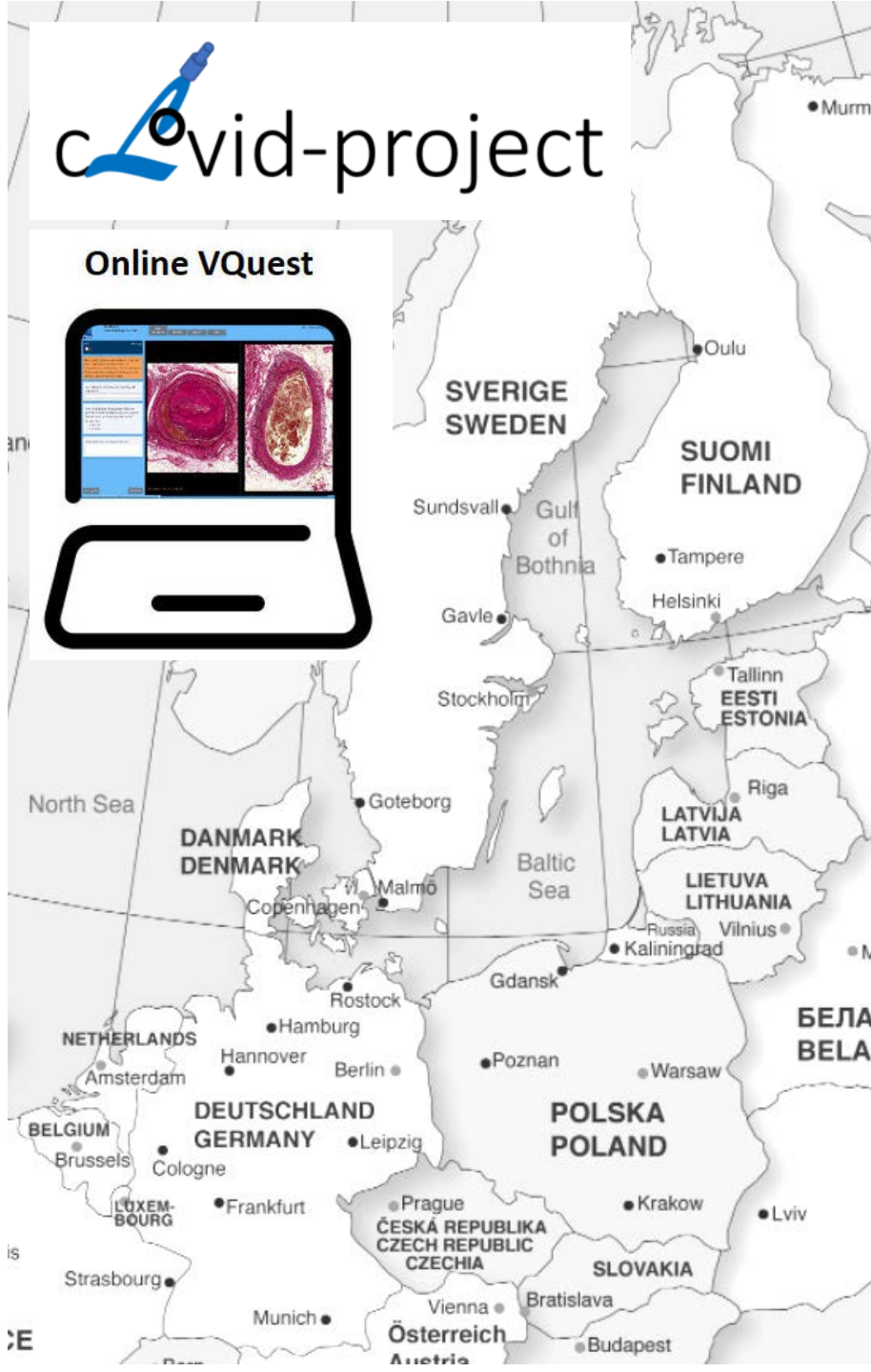

## Online VQuest



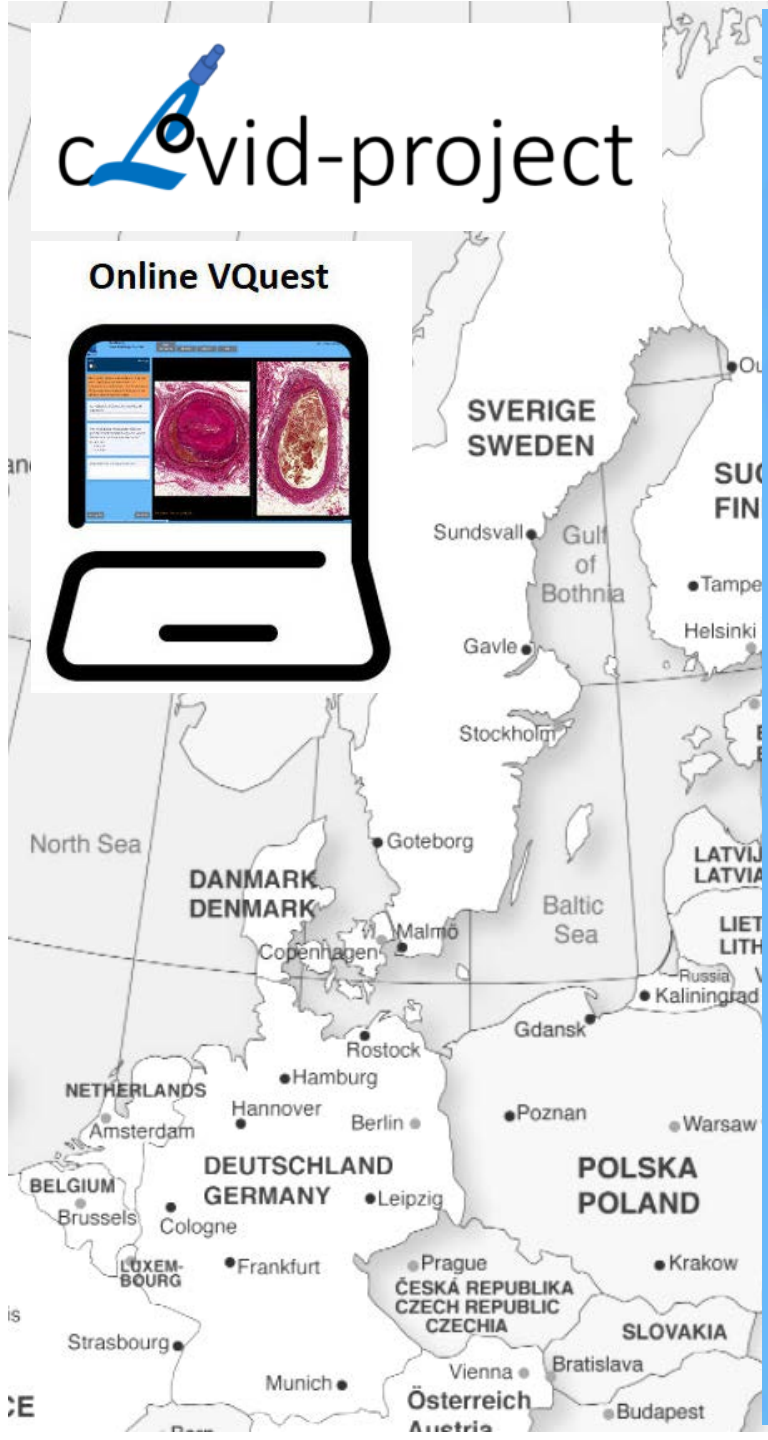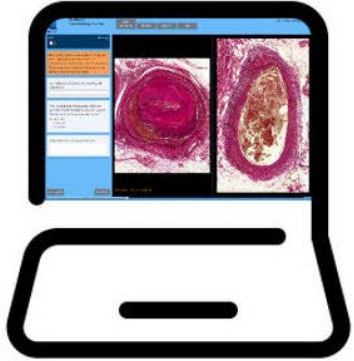# Deliverables

1. Tools
  - VQuest assessment software with viewer for virtual slides (WSI)





## Online VQuest



**VQUEST**

Koen Vincken  
demo cLovid

Reset images Overview Hand in Help

Question 1/1 Lymph node

Specimen of a lymph node.

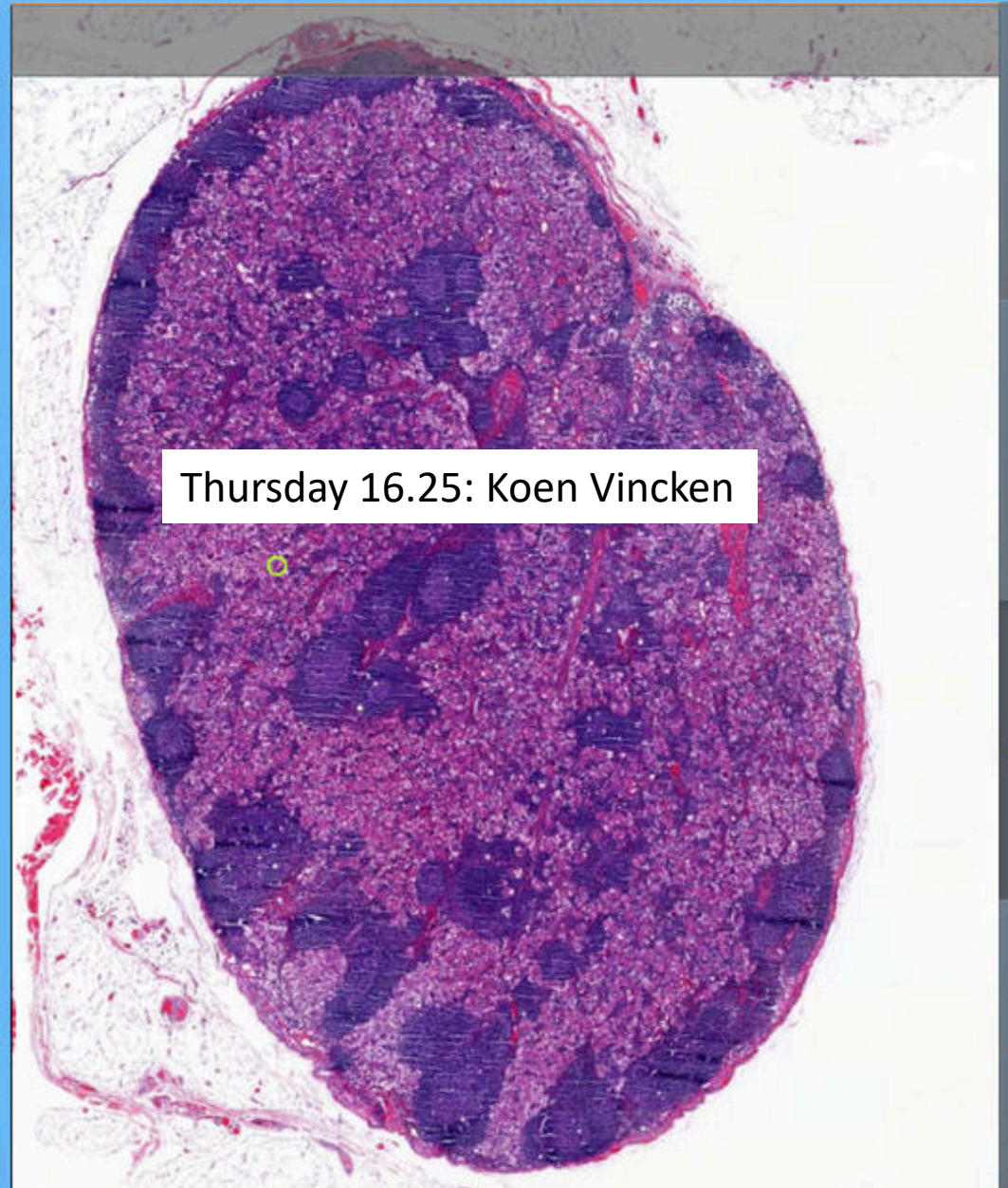
The histological specimen of this lymph node is abnormal because:

- The subcapsular sini can not be detected
- The general structure of the lymph node is abnormal
- The lymph follicles show germinal centres
- The lymphocytes show an abnormal cellular struture
- The lymph node is filled with multi-nucleated giant cells

Place a marker in a region where giant cells can be seen.

Place marker

Previous question Next question



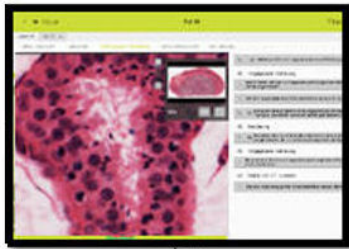Thursday 16.25: Koen Vincken

# covid-project

## Online VQuest



## Learning Dashboard



# Deliverables

## 1. Tools

- VQuest assessment software with viewer for virtual slides (WSI)
- PRISMA Learning dashboard software for small group discussions

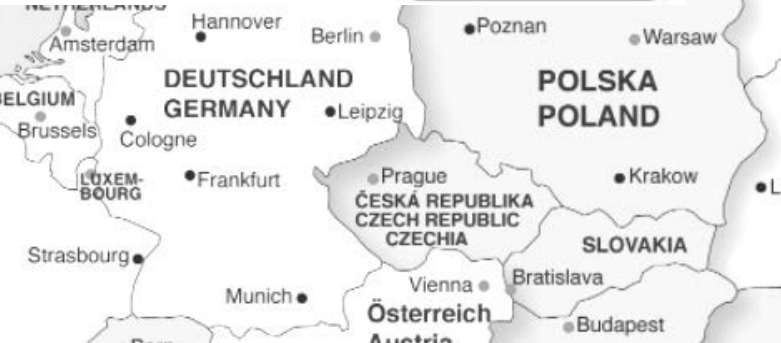
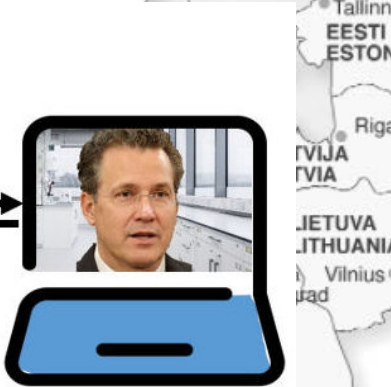
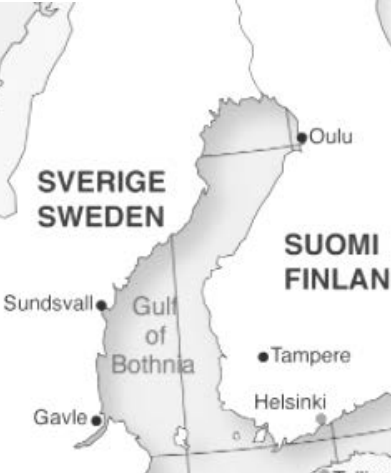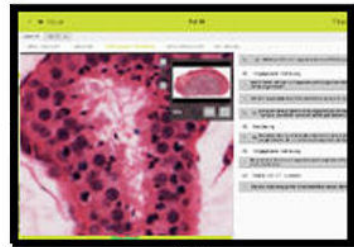# covid-project

## Online VQuest



## Learning Dashboard



VQuest Fall 2A Neuro SS22

Übersicht Fall 1A Neuro SS22 Fall 2A Neuro SS22

CT NATIV CTA UND CTP DSA

82-jähriger Patient Wilfried Schmitz mit plötzlicher Vigilanzminderung, Anisokorie links > rechts, Strecksynergismen, Schutz-ITN, extern Ausschluss ICB - GFR (ml/min/1.73qm): 61.607

Fall 2A: CT nativ

Beschreiben Sie systematisch das native CT Bild:

Markieren Sie die Pathologie im nativen CT: (N = 61)

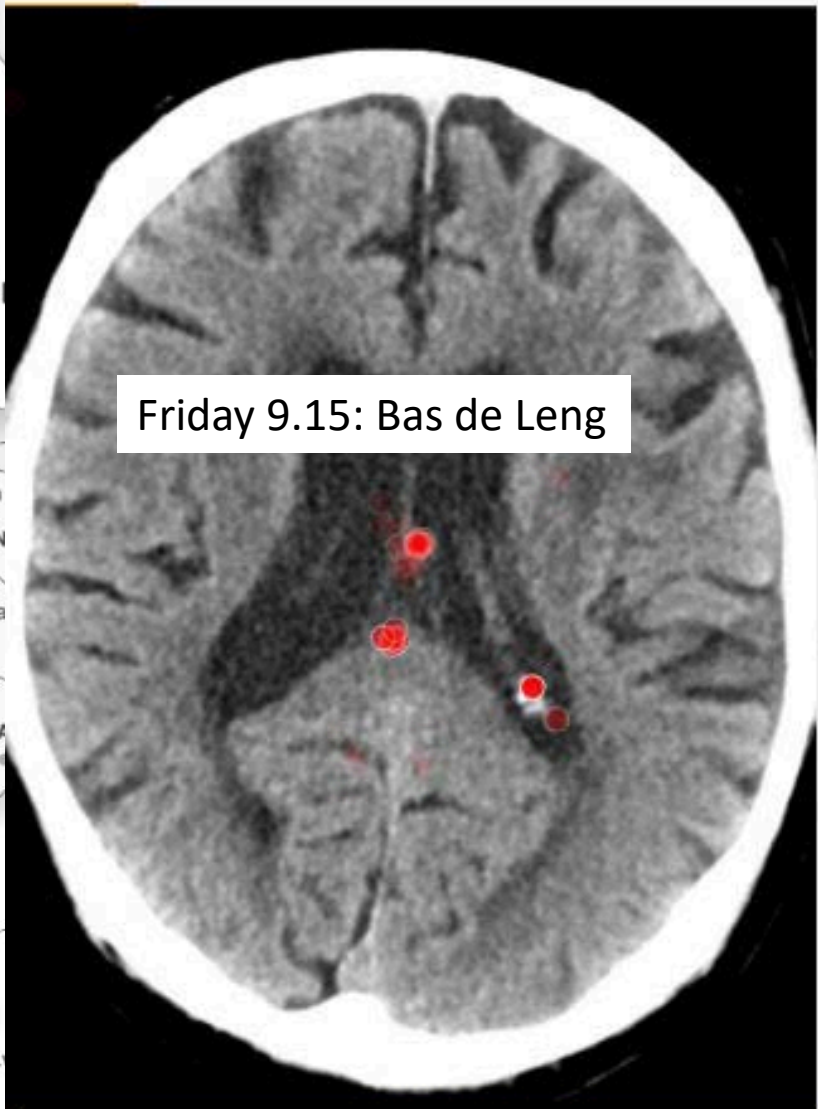
Wie lautet Ihre Verdachtsdiagnose? Häufigkeit ↓

Basilaristhrombose	57
subarachnoidale Blutung	6

Welche ergänzende Bildgebung würden Sie nun empfehlen?

#1 MRT mit KM	#2 CT KM
#3 CT-Angio und CT-Perfusion	#4 CTA CT Diffusion DSA
#5 Im weiteren Verlauf wäre eine MRT-Bildgebung mit KM	#6 T1 3D KM
#15	

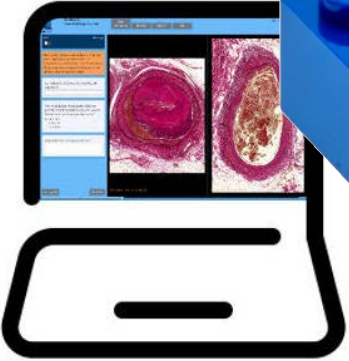Friday 9.15: Bas de Leng



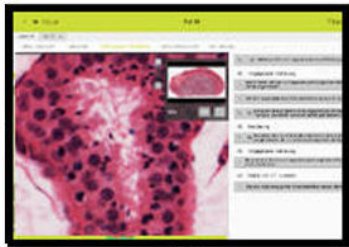


# covid-project

## Online VQuest



## Learning Dashboard



# Deliverables

## 1. Tools

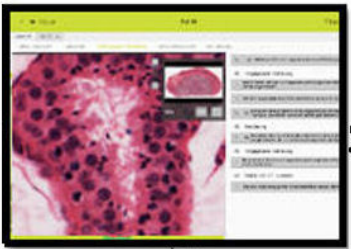
- VQuest assessment software with viewer for virtual slides (WSI)
- Learning Dashboard software for small group discussions
- Videoconferencing software for online communication

# covid-project

## Online VQuest



## Learning Dashboard



# Deliverables

1. Tools
  - VQuest assessment software with viewer for virtual slides (WSI)
  - Learning Dashboard software for small group discussions
  - Videoconferencing software for online communication
2. Didactic training material for teachers in microscopic pathology



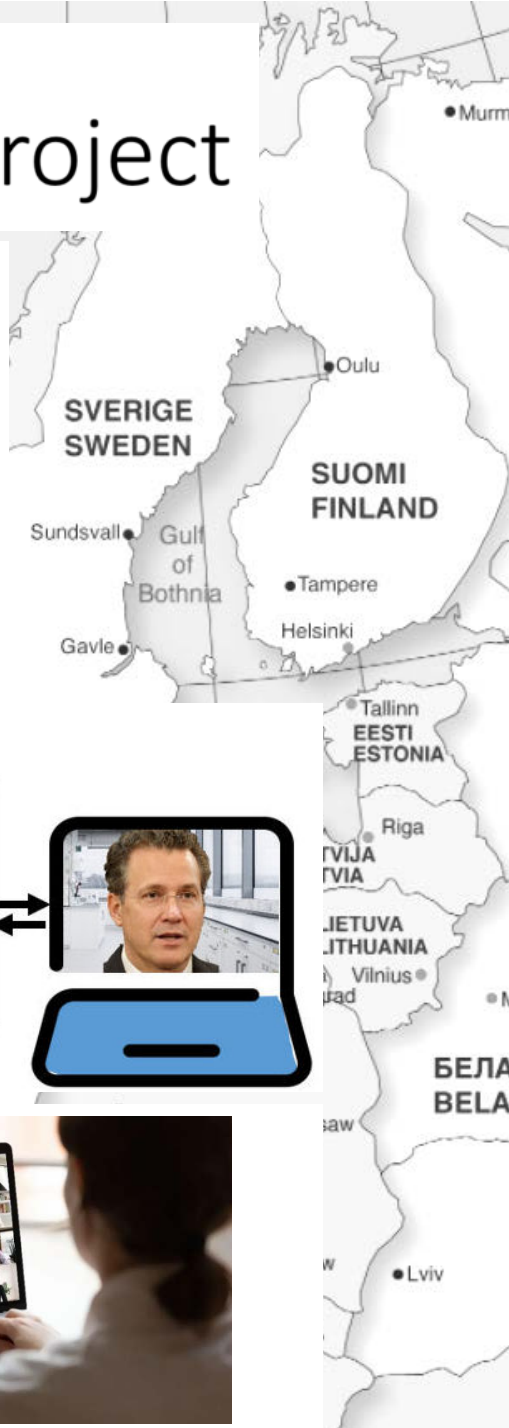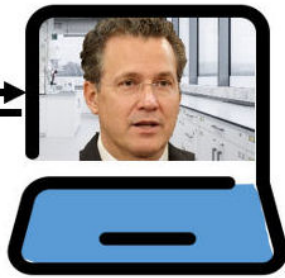

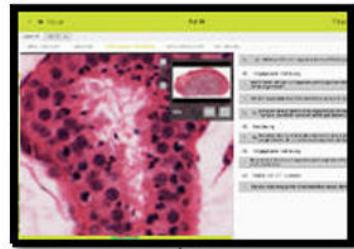
# covid-project

## Online VQuest

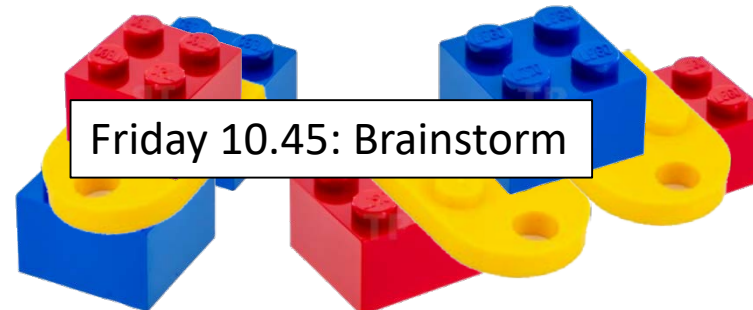

## Learning Dashboard



# Deliverables

1. Tools
  - VQuest assessment software with viewer for virtual slides (WSI)
  - Learning Dashboard software for small group discussions
  - Videoconferencing software for online communication
2. Didactic training material for teachers in microscopic pathology
3. Pilot implementations in undergraduate medical education and their evaluation:
  - Local, national and international



Friday 10.45: Brainstorm